

Radiosurgery: An Adjunct to the Bonded Restoration

By Jeffrey A. Sherman, DDS

General dentistry has undergone extensive changes over the past few years. The media has steadily increased public awareness for a bright, white, cosmetic smile, which has helped change the trend of attracting new patients. Dentists, once faced with restoring teeth with pin built-up amalgams, are now faced with public concern for mercury-free aesthetic restorations. Bonded restorations with increased strength and durability have significantly decreased the use of amalgams as a restoration option.

The senior citizen population is another area of patient awareness. Many patients approaching retirement are no longer edentulous, having undergone periodontal awareness and treatment throughout the years. This population is often plagued with cervical erosion, increased hypersensitivity, and root caries. An aesthetic bonded restoration is indicated due to its retentive and restorative ability and minimal tooth preparation. The tooth with cervical decay is often found to have this decay located subgingivally, which is often a result of poor or compromised oral hygiene in this aging population.

General practitioners have the responsibility of removing all decay and functionally and aesthetically restoring the tooth. They are often confronted with compromised visibility due to subgingival decay, increased bleeding from hyperemic tissue, and hyperplastic uneven gingiva. The bonded restoration therefore requires a dry, bloodless field for maximum strength and aesthetics.

Radiosurgery is the modality of choice for removing gingival tissue and establishing a relatively blood-free environment. This terminology is applied to the most advanced form of electrosurgery and is defined as the passage of a high-frequency radio signal to the surgical site. The radio signal's intensity at the electrode tip creates a volatilization of the tissue cells. It is guided through the tissue-destroying cells and thus creates an incision. Heat produced by the resistance of the tissue cells to the radio signal helps establish hemostasis. More specifically, radiosurgery uses a high-frequency (3.0 to 4.0 MHz) radio signal compared to the lower frequency (1.0 to 2.9 MHz) used by the electrosurgical

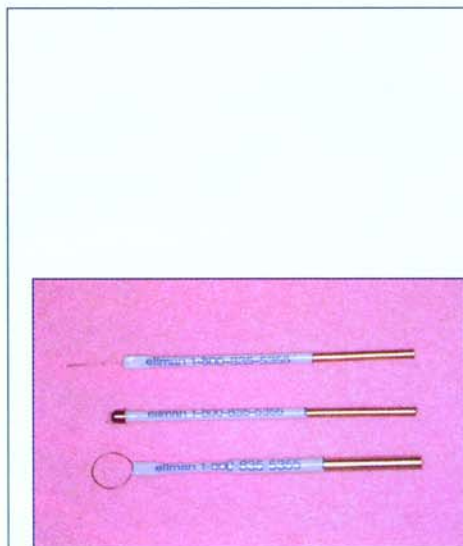


Figure 1. The straight wire and ball- and pencil-shaped electrodes used for radiosurgery.

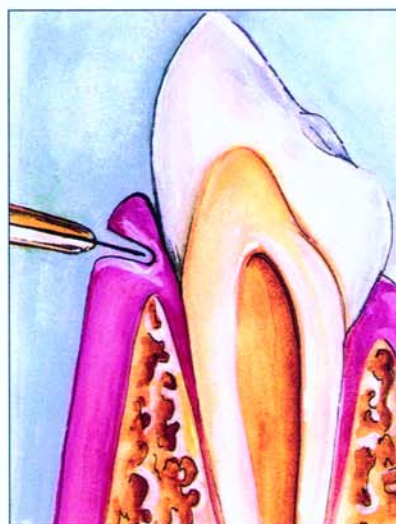


Figure 2. A straight wire or Vari-Tip electrode is used to remove tissue when performing a gingivectomy.

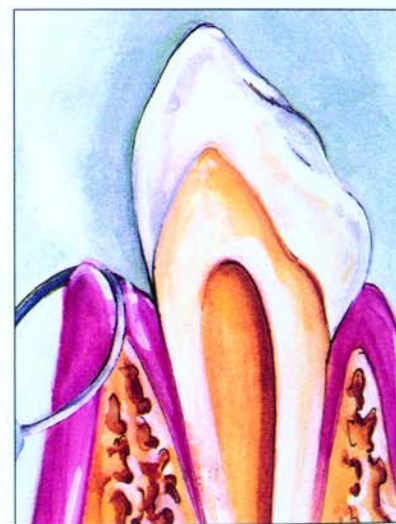


Figure 3. A loop electrode is used to contour tissue and perform a gingivoplasty.

instrument. It has been shown that a higher frequency produces less tissue alteration and heat.¹⁴ Because of its hemostatic nature, radiosurgery produces a more accurate and aesthetic incision and minimizes patient awareness. This modality has proven to be a necessary adjunct to successful bonded restorations.⁵⁻⁷

A more extensive review of radiosurgical procedures can be found in *Oral Radiosurgery—An Illustrated Clinical Guide, Second Edition* (Ellman International). The author recommends that practitioners enroll in participation courses to become fully versed in all facets of radiosurgery. Dentists can be compensated for using radiosurgery according to the appropriate CDT code. Code No. 04211 is used for gingivectomy per tooth, and No. 04210 is used for gingivectomy/gingivoplasty per quadrant.

The radiosurgical incision is a pressureless, microsmooth incision that produces the least amount of lateral heat to the surrounding tissue. Lateral heat is the heat produced from the resistance created between the tissue and the radio signal. It is also a product of the time of contact with the tissue and power intensity, radiosurgical frequency, and waveform used. The high-frequency signal passes through the tissue with less resistance than the lower frequency radiowave of the electrosurgical instru-

ment.^{14,7} Therefore, a fine, predictable incision with various degrees of hemostasis is produced.

There are presently four different radiosurgical waveforms available. The number of waveforms included with any surgical instrument varies from one manufacturer to the next; therefore, unit selection must be thoroughly researched. A fully rectified waveform is used for simultaneously establishing cutting and hemostasis. Fully rectified filtered waveforms provide the finest microsmooth incisions with only minimal hemostasis. The partially rectified waveform produces hemostasis of the soft tissue, and a fulguration waveform establishes hemostasis in close proximity to the bone and destroys any cyst or granulomatous tissue remnants.

Radiosurgical instruments feature a wide variety of electrode-cutting tips, including a variety of straight wires for incisions, ball and pencil shapes for coagulation, and loop and diamond shapes for planing or recontouring tissue (Figure 1). A Vari-tip (118) (Ellman) electrode is a straight wire electrode with a variable length wire. This electrode has achieved popularity because it enables doctors to incise tissue to a predetermined depth. (Figures 2 and 3). The pencil-shaped electrodes (113F and 117) are used for interproximally establishing hemostasis with pinpoint accuracy.

Hemostasis is accomplished by first drying the area with a cotton roll or air syringe to facilitate cauterization of the vessel. The fully rectified waveform is used to incise tissue that exposes subgingival decay or root caries (Figure 4). This waveform adequately removes tissue and establishes hemostasis, so the Vari-tip straight wire electrode is the ideal tip for removing tissue. Oozing areas can be controlled with a pencil-shape electrode and a partially rectified waveform, which is paramount for establishing a dry field for enhanced operator visibility and bond strength.

CASE STUDY

A 47-year-old female presented for routine dental treatment. Clinical and radiographic examination revealed extensive areas of cervical erosion and subgingival decay. It was decided that radiosurgery would be used to expose the subgingival decay and establish hemostasis for a stronger, more aesthetic restoration. A gingivoplasty was performed to reshape the abnormal form of the gingiva (Figure 5) and expose any areas of subgingival decay. Tissue removal was performed using the fully rectified waveform. This provided the advantage of cutting while establishing coagulation (Figure 6). Any areas of isolated oozing were dried and cauterized using a partially rectified waveform (Figure

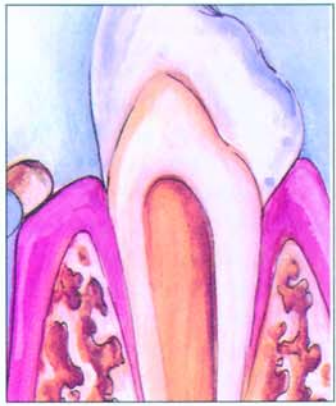

Figure 4. Hemostasis is obtained using a ball electrode and a partially rectified waveform.

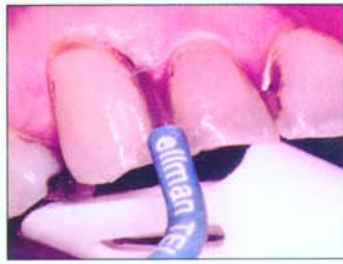

Figure 5. A Vari-tip (118) electrode and a fully rectified waveform were used to expose the subgingival decay on the cuspid.

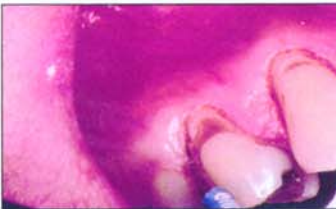


Figure 6. The gingivectomy procedure was continued onto the premolar with the Vari-tip electrode. The fully rectified waveform minimized the amount of bleeding, increasing the doctor's visibility.

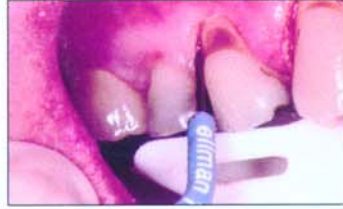

Figure 7. A pencil-point (113F) electrode was used with a partially rectified waveform to ensure total hemostasis, allowing for a more durable and aesthetic restoration.

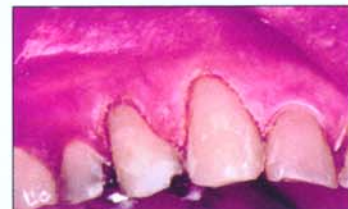

Figure 8. Postoperative view with bonded restorations placed.

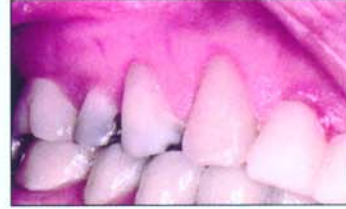

Figure 9. Postoperative view depicting healing following 4 weeks.

7). The surgical site was then irrigated with Peridex (Procter & Gamble) and covered with several layers of Tincture of Myrrh and Benzoin. More extensive areas of surgery were protected with a Coe-Pak (GC America) periodontal dressing (Figures 8 and 9).

CONCLUSION

Radiosurgery is one of the most important and versatile instruments used in dentistry. Its applications are clearly paramount for establishing more aesthetic, blood-free, bonded restorations. ♦

References

1. Raus P, Mentens E. Evaluation of radiosurgery as a cosmetic surgery technique. *Int J Aesthetic Restor Surg*. 1997;5(2):96-100.
2. Maness W, Clark R. Histologic evaluation of electrosurgery with varying frequency and waveform. *J Prosthet Dent*. 1978;40:304.
3. Ferris R. Periodontal flap management prepared with radiosurgery. *Dent Econ*. 1993;83(6):43-46.
4. Oringer M. *Electrosurgery in Dentistry*. Philadelphia, Pa: WB Saunders;1975.

5. Berland L, Westbrook P. Implant crowns and veneers: using nitrogen and heat-pressed microhybrids. *Dent Today*. 1998;17(5):84-87.
6. Orent T. Enhance your cosmetic cases tenfold while dramatically increasing profitability. *Profit Dentist*. 1998;5:14-17.
7. Sherman J. *Oral Radiosurgery: An Intellectual Clinical Guide*. London, England: Martin Dunitz, Ltd;1997.

Dr. Sherman is currently the executive director of the World Academy of Radiosurgery, past president of the American Academy of Dental Electrosurgery, a diplomate of the American Board of Oral Electrosurgery, and a fellow in the American and International Colleges of Dentists. Intensely involved with research and development of radiosurgery in the dental profession, Dr. Sherman has conducted extensive research and clinical trials, written two textbooks on electrosurgery/radiosurgery, lectured, produced a radiosurgery video, and authored numerous articles in international and national journals. He can be reached at (516) 567-2100.

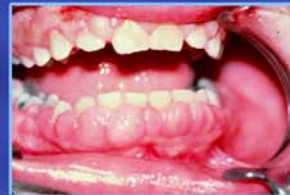ellman

High Frequency Radiosurgery

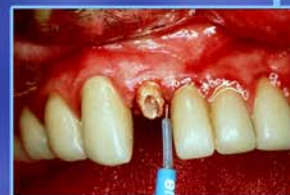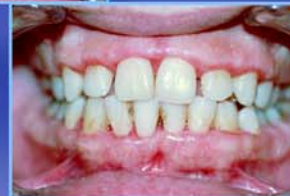Dento-Surg⁹⁰ FFP



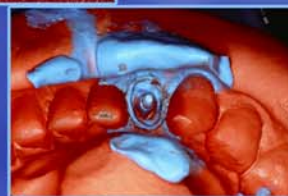
Radiosurgery Maximizes Clinical Excellence



Removal of Hyperplasia




Crown and Bridge



"This tremendous piece of equipment not only saves me valuable time, but it also alleviates doctor and patient stress related to bleeding problems. I would recommend that every dental practitioner purchase an Ellman Dento-Surg. This is THE ONE financial expenditure that I have made of which I can truthfully say, 'Money well spent!'"
L.R. Burke, D.D.S.

"My only complaint? Why did I wait so long!"
P.J. Lepeak, D.D.S.

"I have three (3) Ellman units now ranging from 10 to 14 years old, and they have never seen the inside of a service shop. The Ellman Radiosurgery unit is a true 'workhorse' that seems to disregard continual usage."
Dr. R.B.L. Warwick



Textbook by
Jeffrey A. Sherman, DDS



ellman international inc.

3333 Royal Avenue, Oceanside, NY 11572

800-835-5355 • 516-594-333 • Fax: 516-569-0054 • www.ellman.com