

## Review

# The Value of Radiosurgery in Oculoplastics

Jay Justin Older, M.D.

*Department of Ophthalmology, University of South Florida, College of Medicine, Tampa, Florida, U.S.A.*

---

**Purpose:** To present the value of radiosurgery in oculoplastic procedures.

**Methods:** My experience of 3 years and approximately 1000 oculoplastic procedures using radiosurgery was synthesized. The radiosurgical techniques that I have found useful are presented.

**Conclusions:** Radiosurgery is an excellent surgical tool for performing oculoplastic procedures because it coagulates blood vessels as it cuts through tissue. This allows less bleeding during surgery, which translates in better visualization of the tissue planes and a more rapid procedure.

---

Radiosurgery is the passage of high-frequency radio waves through tissue for the purpose of dissection. By using the appropriate waveform and wave frequency, the surgeon can create skin incisions and deep tissue dissection with little destruction of the surrounding structures. Excellent hemostasis during dissection is achieved by using the correct waveform and proper electrode. Minimal tissue destruction and good hemostasis result in minimal swelling and bruising with excellent wound healing.

Dr. Irving Ellman, a practicing dentist and electronic engineer, developed the Surgitron that produced high-frequency electrical current that would cut tissue with minimal lateral heat and damage. In 1973, Dr. Ellman was granted a patent on 3.8-megahertz and 4 therapeutic waveforms. The unit was developed with solid-state design, but there was some leakage of radio waves resulting in frequency variation between 3.4 and 3.8 megahertz. In 1995, Ellman International used microchips in designing the Surgitron Dual Frequency and was able to produce a consistent output of 4 megahertz. This higher frequency resulted in even less lateral heat.

The Ellman Surgitron first became popular in the field of dentistry,<sup>1–3</sup> and its value was later appreciated for the removal of skin lesions.<sup>4–9</sup> Radiosurgery is now used in gynecology,<sup>10–12</sup> otolaryngology,<sup>13</sup> general practice,<sup>14,15</sup> and veterinary medicine.<sup>16</sup> Neurosurgeons find radiosurgery useful in the treatment of discogenic low back pain,<sup>17</sup> and dermatologists use it for the obliteration of facial telangiectasias.<sup>18</sup>

Ophthalmologists are finding radiosurgery to be useful in oculoplastic procedures<sup>19–24</sup> and in retinal procedures to drain subretinal fluid.<sup>25</sup> I find that it replaces the knife in most cases and facilitates my oculoplastic procedures.

### PRINCIPLES OF RADIOSURGERY

The principle of radiosurgery is that a 4-megahertz radio wave (above AM and below FM) passes through tissue from an active electrode to a passive electrode. The resistance of the tissues causes volatilization of the cells at the tip of the electrode. This narrow path of cell destruction creates a smooth incision with minimal lateral cell damage.

Several factors affect the amount of lateral heat generated. By varying these parameters, the amount of cutting and coagulation can be varied. By increasing the diameter of the electrode, the intensity of the power and the time the electrode is in contact with the tissues causes more lateral heat. Both the waveform and the frequency

---

Accepted September 24, 2001.

Under certain circumstances, Dr. Older receives honoraria and travel expenses from Ellman International.

Address correspondence and reprint requests to Dr. J. Justin Older, Contemporary Eye Care Specialists, 4444 East Fletcher Avenue, Suite D, Tampa, FL 33613–4937. E-mail jolder1@tampabay.rr.com

of the current affect the amount of lateral heat generated. The fully rectified filtered waveform, which is a continuous wave, causes the least amount of lateral heat. By interrupting the continuous flow to varying degrees, the amount of lateral heat is increased. The amount of lateral heat generated is inversely proportional to the frequency of the signal. The advantage of this very high frequency is that cutting and hemostasis can be produced with much less lateral heat and tissue destruction than with other electrical instruments that use a much lower frequency.

Using hamster tongues and a machine that controlled speed and depth of cut, Maness and his colleagues<sup>26</sup> showed that less lateral tissue destruction occurred with 4.0 than with 2.8 or 1.7 megahertz. They also demonstrated that the continuous waveform produced less injury than the fully rectified waveform. Olivar and his colleagues<sup>27</sup> microscopically examined fallopian tubes removed for tuboplasty to evaluate the amount of damage received by the surrounding healthy tissue. When comparing radiosurgery with electrocautery and several different lasers, they found that the least amount of lateral thermal damage was caused by radiosurgery.

The Surgitron Dual Frequency produces 4 waveforms with a 4-megahertz frequency. These waveforms are fully rectified filtered, fully rectified, partially rectified, and fulguration. The unit also produces a bipolar current at 1.7 megahertz that is used for bipolar coagulation.

To create high-frequency current, household current (60 cycles per second) must be made to oscillate at hundreds of thousands of cycles per second. This current is in the form of an alternating sine wave. If only the first half of each individual cycle of alternating is converted in high-frequency energy, it is referred to as partially rectified. The second half of each cycle is damped out. The partially rectified waveform is an intermittent flow of high-frequency current that produces more lateral heat and is good for hemostasis. However, it can also be used for soft tissue dissection with minimal bleeding. If both halves of the sine wave are converted into high-frequency energy, a fully rectified current is produced. Since each individual cycle begins and returns to zero, there is some damping, which results in some coagulation. The fully rectified waveform is a full wave current that produces cutting with some coagulation and is good for tissue dissection other than skin. If it is used for skin incisions, there is a higher risk of scar formation. By using additional electronic components to filter out the constrictions as each wave begins and ends at zero, the fully rectified current can be converted to a continuous current without an appreciable coagulation effect.<sup>28</sup>

This fully rectified filtered waveform produces a

**TABLE 1.** *Ellman settings*

Wave Form	Setting	Activity	Coagulation
Fully rectified filtered	Cut	Skin incisions	Minimal
Fully rectified	Cut/coag	Subcutaneous dissection	Moderate
Partially rectified	Hemo	Deep dissection and hemostasis	Good

smooth cut with the least amount of lateral heat and tissue shrinkage. It is best for skin incisions (Table 1).

The fulguration waveform produces the greater amount of lateral heat and is primarily used for tissue destruction.<sup>29</sup> I have not found this waveform useful in oculoplastic surgery.

## TECHNIQUE

### General Principles

A smoke evacuation device should always be used to catch the plume that is generated while dissecting or coagulating with the unipolar or bipolar hand pieces. Reports have indicated that the smoke byproduct from thermal destruction of tissue by an electrosurgical unit can contain toxic gases such as hydrogen cyanide, benzene, and formaldehyde. The plume can also contain live cellular material such as blood fragments and viruses. The National Institute for Occupational Safety and Health published a report stating that "Generally speaking, the use of smoke evacuators is more effective than room suction systems to control the generated smoke from non-endoscopic laser/electric surgical procedures."<sup>30,31</sup> (Author's comment: I operate at several facilities and use both room suction systems and smoke evacuators. Smoke evacuators have a higher noise level, but this has not caused communication problems between the surgeon and the assistants.) A very light touch should be used because the electrode can cut through tissue very easily and quickly. Corneal protectors are advised for increased patient safety. Numbers and settings in the following discussion refers to the Dual Frequency Surgitron only. It is recommended that the operating surgeon try several power settings for each combination of electrode and waveform. The goal is to use enough power to have the electrode slide easily through the tissues but not to have any sparking. The power settings mentioned in the following discussion have been found useful by the author.

### Skin Incisions

Varying the waveform and the type of electrode allows different maneuvers with minimal bleeding. For eyelid crease skin incisions, the A-8 wire electrode (0.007 inches) at a power setting of 40 on the Surgitron Dual Frequency Unit is used. The waveform is fully rectified filtered and is designated as "cut" on the unit. This is the continuous wave that gives the least lateral heat. The wounds heal the same as with a scalpel (Table 2).

The A-10 electrode is thinner (0.004 inches) and gives even less lateral heat, but it bends easily and is, therefore, more difficult to handle. This wire electrode is very useful for the removal of malignant lesions in which microscopic evaluation of the margins is required. The setting is on "cut" with a power of 40 on the Surgitron Dual Frequency. With this technique, pathologists find no tissue damage that might interfere with an accurate evaluation of the margins.

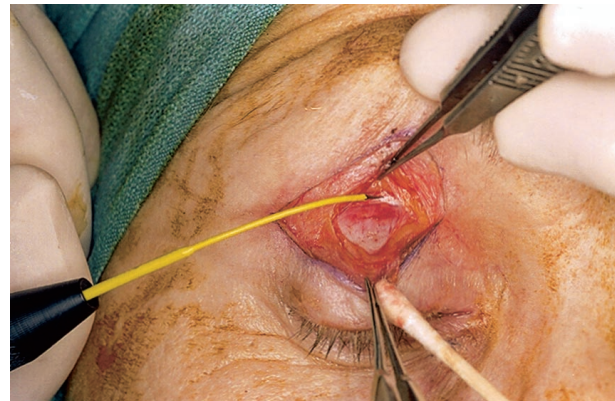
For a retroauricular skin graft, the A-8 electrode on "cut/coag" and power of 50 gives a clean dissection, and the wounds heal well. This is a fully rectified waveform and gives more lateral heat than the "cut" setting but better hemostasis. Since a small scar in this area is not of concern, the improved hemostasis facilitates the procedure.

### Soft Tissue Dissection

Smooth cutting with hemostasis is the value of radiosurgery when dissecting tissue below the skin. To obtain the best hemostasis, the fully rectified (cut/coag) or partially rectified (hemo) setting is used. (The words "cut/coag" and "hemo" are the settings as written on the base unit of the Ellman Dual Frequency Surgitron. "Hemo" refers to hemostasis and "coag" is the abbreviation for coagulation.) The "hemo" setting gives the better hemostasis, but if the tissue is too firm, the "cut/coag" setting is chosen. The Empire Needle is extremely versatile. This electrode is fully insulated except for the tip, which is cone shaped. Cutting is best done with the tip, but hemostasis can be obtained by touching the side of the cone to the bleeding vessel.

**TABLE 2.** Choice of electrode size

Procedure	Electrode	Surgitron setting
Skin incision	A-10 or A-8	Cut
Biopsy	A-10	Cut
Soft tissue	Empire	Hemo or cut/coag
Conjunctiva	A-8 or Empire	Hemo or cut/coag
Trichiasis	Trichiasis electrode	Hemo with very low power



**FIG. 1.** Upper lid ptosis repair with the Empire Needle. Note minimal swelling and distortion of tissues.

Larger bleeding vessels can be coagulated with the bipolar forceps that use the lower frequency of 1.7 megahertz.

A commonly performed oculoplastic procedure is a blepharoplasty combined with levator advancement through a skin incision. Once the skin incision is made with the A-8 electrode, the rest of the dissection is done with the Empire Needle on a hemo setting. Removal of the skin muscle flap and exposure of the levator aponeurosis and tarsus can be done with minimal bleeding. This allows excellent visualization of the anatomic structures, which, in turn, facilitates the dissection (Figure 1). Removal of a retroauricular skin graft can be done easily with the Empire Needle on "hemo." If dissection is not smooth enough with the Empire Needle on "hemo" or "cut/coag," the A-8 electrode on "hemo" or "cut/coag" is chosen.

Removing the Müller muscle from underlying conjunctiva in a transcutaneous approach for upper eyelid retraction may be quite bloody with scissors. With the use of the Empire Needle, the muscle can be separated from the conjunctiva with very little bleeding. Any bleeding that does occur can be stopped by touching the bleeding site with the side of the Empire Needle set on "hemo." It is important to have the corneal protector in place since the bleeding site may be in the conjunctiva. Since there is so little lateral heat generated, a buttonhole in the conjunctiva rarely appears. If one occurs, it is repaired with a 7-0 chromic suture.

### Tarsus

Radiosurgery facilitates cutting through tarsus with minimal bleeding. To create a tarso-conjunctival flap for use in the Hughes procedure, the A-8 electrode on

“cut/coag” is used. For removal of a tumor that needs microscopic evaluation of the margins, the A-10 electrode is used with a “cut” setting. This electrode slides through tarsus very easily.

Removing palpebral conjunctiva to create a tarsal strip can be relatively bloody with a scalpel. With the Empire Needle on “hemo,” the palpebral conjunctiva and the eyelid margin epithelium can be wiped from the tarsus with no bleeding.

### Conjunctiva

For a transconjunctival lower lid blepharoplasty, the A-8 electrode on “cut/coag” is used to incise conjunctiva. This same combination is excellent for removing an ellipse of conjunctiva inferior to the punctum for correction of punctal ectropion. This is also used for cutting conjunctiva when making a tarsoconjunctival flap in the Hughes procedure.

### Fat

Removal of fat in an upper or lower blepharoplasty is best done with the Empire Needle on “hemo.” To keep bleeding to an absolute minimum, the side of the Empire Needle is used to increase the surface area touching the tissue. By enlarging the surface area and moving the electrode slowly, more lateral heat with better hemostasis is obtained. For coagulation of larger vessels, the bipolar forceps with the bipolar setting seems best. This setting gives the lower frequency of 1.7 megahertz, and more lateral heat is obtained.

### Trichiasis

Trichiasis can be eliminated one lash at a time or by cutting out the tissue that holds the abnormal lashes. To remove individual cilia, the 0.004 insulated electrode is inserted down the shaft of the eyelash. With the power at 10 or less on the Surgitron Dual Frequency and the setting on “hemo,” the surgeon taps quickly on the foot pedal several times. Once the follicle is killed, the lash can be removed without any resistance.

To eliminate a group of lashes, the A-8 electrode on “cut/coag” is used to cut away the tissue that holds the lashes. The area is allowed to granulate. The skin is often recessed away from the eyelid margin in this area. This helps to prevent the skin from growing over the granulated area. If the skin does grow over the surgical site, the small skin hairs of the skin or the skin itself might touch the cornea.

### Telangiectasis

Superficial telangiectatic vessels on the eyelids and face can be eliminated with radiosurgery. The insulated wire that is used for trichiasis repair is touched to the skin overlying the vessel. No anesthetic is used since the discomfort is minimal. A cream such as 2.5% lidocaine and 2.5% prilocaine (EMLA Cream, Astra USA, Inc., Westborough, Mass.) can be applied if the patient wishes. Local injection will distort the vessels. With the Dual Frequency Surgitron on “hemo” or “cut/coag,” the wire electrode is touched to the skin over the vessel. The procedure is begun with a low power of 1, which is increased until the vessel begins to blanch. The thin, insulated trichiasis wire is excellent for this process. The foot pedal is tapped for a short burst of energy. The vessel usually disappears instantly. There might be a small epithelial defect that heals quickly, or minimal bleeding may occur. This treatment should be continued every 1 to 2 mm along the vessel. Repeat treatments of some of the vessels may be necessary.

### Dacryocystorhinostomy

Radiosurgery can be used in the transnasal<sup>32</sup> or the cutaneous approach. I prefer the external route. As with other skin incisions, the A-8 wire on cut is used. Dissection is continued to the anterior lacrimal crest with the Empire Needle on “hemo.” Since this is a very vascular area, the bipolar forceps might be needed to help control bleeding. After the osteotomy is made, anterior flaps of lacrimal sac of nasal mucosa are fashioned with the A-8 wire on “hemo” or “cut/coag.” There is much less bleeding than with a knife or scissors and better preservation of the nasal mucosa and lacrimal sac than with an electrocautery device.

### DISCUSSION

The greatest advantage of radiosurgery is that it allows precision dissection with excellent hemostasis. The wounds heal as well as with a scalpel. There is much less bleeding, resulting in less bruising during the healing period. With less bruising, I believe there is less postoperative discomfort and quicker healing. However, this is based on my observations, not a scientific study. I find this technique much easier and quicker than with a scalpel. The assistant does not have to hold the skin on stretch but does have to hold the suction for the plume. There is much less lateral heat than with electrocautery devices, resulting in less surrounding tissue damage.

In my experience, the Dual Frequency Surgitron gives dissecting hemostasis similar to that of a laser. However,

skin incisions heal as quickly as incisions made with a scalpel, and I can remove skin sutures in 5 to 6 days. I also believe the learning curve is quicker and easier than with a laser used for dissecting. As other specialties in medicine appreciate the value of radiosurgery, I believe there will be many more uses for this expanding technology.

## REFERENCES

- Sherman JA. *Oral Radiosurgery, An Illustrated Clinical Guide*. 2nd ed. London: Martin Dunitz Ltd; 1997.
- Goldstein AA. Radiosurgery in dentistry. *Journal Dentaire du Québec Dental Journal* 1977;14:1–18.
- Kalkwarf KL, Krejci RF, Wentz FM. Healing of electrosurgical incisions in gingiva: early histologic observations in adult men. *J Prosthet Dent* 1981;46:662–9.
- Waldman SR. Cutaneous procedures: Management of superficial skin lesions in a cosmetic surgery practice. In: Stucker FJ, ed. *Plastic and reconstructive surgery of the head and neck. Proceedings of the fifth international symposium. American Academy of Facial Plastic and Reconstructive Surgery*. Part 13/Chapter 120. Philadelphia: BC Decker; 1991:595–8.
- Cresswell CC. Introduction to electrosurgery. *J Br Podiatric Med* 1992;47:11–5.
- Wyre HW, Stolar R. Extirpation of warts by a loop electrode and cutting current. *J Dermatol Surg Oncol* 1977;3:520–2.
- Toombs EL, Peck GL. Electrosurgical treatment of etretinate-resistant Darier's disease. *J Dermatol Surg Oncol* 1989;15:1277–80.
- Hofmann A, Wüstner M, Ciric B. Radiowave surgery case report. *Int J Aesthetic Restorative Surg* 1996;4:131–2.
- Kadry MK, Eshak EA, Zaki MS, et al. Clinical and histopathological evaluation of radiofrequency in the surgical management of malignant skin lesions. *Egyptian J Plast Reconstr Surg* 1995;19:93–8.
- Kainz C, Tempfer C, Sliutz G, et al. Radiosurgery in the management of cervical intraepithelial neoplasia. *J Reprod Med* 1996;41:409–14.
- Saidi MH, Setzler FD, Sadler RK, et al. Comparison of office loop electrosurgical conization and cold knife conization. *J Am Assoc Gynecol Laparosc* 1994;1:135–9.
- Turner RJ, Cohen RA, Voet RL, et al. Analysis of tissue margins of cone biopsy specimens obtained with "cold knife," CO<sub>2</sub> and Nd:YAG lasers and a radiofrequency surgical unit. *J Reprod Med* 1992;37:607–10.
- Nikolayev MP, Ulyanov YP, Kutin GA, et al. Role of radiosurgery in otorhinolaryngology. *Int Med J* 1998;11/12:933–5.
- Brown JS. Radio-surgery. In: *Minor Surgery. A Text and Atlas*. 3rd ed. London: Arnold. Co-published in USA: New York: Oxford University Press; 1999:300–26.
- Brown JS. Radio surgery for minor operations. *Cosmetic Dermatol* 2000;July:33–36.
- Altman RB. Radiosurgery. In: *Seminars in Avian and Exotic Pet Medicine*. Philadelphia: WB Saunders; 2000:180–3.
- Yeung AT, Morrison PC, Felts MS, Carter JL. Intradiscal thermal therapy for discogenic low back pain. In: Savitz MH, Chiu JC, Yeung AT, eds. *The Practice of Minimally Invasive Spinal Technique*. 1st ed. Lima, Ohio: AAMISMS Education, LLC, CSS; 2000:237–42.
- Harris DR, Noodleman R. Using a low current radiosurgical unit to obliterate facial telangiectasias. *J Dermatol Surg Oncol* 1991;17:382–4.
- Javate RM, Campomanes BS, Co ND, et al. The endoscope and the radiofrequency unit in DCR surgery. *Ophthal Plast Reconstr Surg* 1995;11:54–8.
- Dutton JJ, Tawfik HA, DeBacker CM, Lipham WJ. Anterior tarsal V-wedge resection for cicatricial entropion. *Ophthal Plast Reconstr Surg* 2000;16:126–30.
- Bosniak S, Zilkha MC. Cosmetic radio-blepharoplasty. *Int J Aesthetic Restorative Surg* 1995;3:53–6.
- Raus P, Mertens E. Evaluation of radiosurgery as a cosmetic surgery technique. *Int J Aesthetic Restorative Surg* 1997;5:96–100.
- Hurwitz JJ, Johnson D, Howarth D, Molgat YM. High-frequency radio wave electrosection of full-thickness eyelid tissues. *Can J Ophthalmol* 1993;28:28–31.
- Murube J, Murube E. Treatment of dry eye by blocking the lacrimal canaliculi. *Surv Ophthalmol* 1996;40:463–80.
- Gallenga PE, Mastropasqua L, Carpineto P. Drainage of subretinal fluid with a radiosurgical instrument: a preliminary report. *Retina* 1998;18:555–6.
- Maness WL, Roeber FW, Clark RE, et al. Histologic evaluation of electrosurgery with varying frequency and waveform. *J Prosthet Dent* 1978;40:304–8.
- Olivar AC, Forouhar FA, Gillies MS, Servanski DR. Transmission electron microscopy: evaluation of damage in human oviducts caused by different surgical instruments. *Ann Clin Lab Sci* 1999;29:281–5.
- Pollack SV. Electrosurgical outputs and their effects. In: *Electrosurgery of the Skin*. New York: Churchill Livingstone; 1991:21–3.
- Sherman JA. Waveform types and properties. In: *Oral Radiosurgery, an Illustrated Clinical Guide*. 2nd ed. London: Martin Dunitz Ltd; 1997:9–14.
- NIOSH. *Control of smoke from laser/electric surgical procedures*. USDHHS, CDC: 1996; Publication 96–128.
- Brandon HJ, Young VL. Characterization and removal of electrosurgical smoke. *Surg Services Management* 1997;3:14–6.
- Javate RM, Pamintuan FG. Endoscopic radiofrequency-assisted dacryocystorhinostomy and the Griffiths collar button: operative techniques. *Oculoplastic Orbital Reconstr Surg* 1998;1:73–80.