

## Comparative Study between Radiofrequency Sinus Excision and Open Excision in Sacro-Coccygeal Pilonidal Sinus Disease

Pravin J. Gupta

Gupta Nursing Home, Nagpur, India

### Key Words

Pilonidal sinus · Excision and open wound · Radiofrequency · Recurrence

### Abstract

**Aim:** Evaluation of outcome of pilonidal sinus excision using a radiofrequency device and comparing its results with excision and open granulation procedure. **Methods:** Patients with sacro-coccygeal pilonidal sinus disease (n = 44) were randomly assigned to undergo either a wide excision and healing by open granulation procedure [WEG] (n = 23) or a radiofrequency sinus excision [RSE] (n = 21). An Ellman radiofrequency generator was used for RSE. Intra- and postoperative events and outcome data were evaluated and analyzed by Student's unpaired t test and  $\chi^2$  test. **Results:** The significant differences in the two groups WEG and RSE were as follows: mean hospital stay (47 vs. 10 h,  $p < 0.05$ ), period off work (29 vs. 8 days,  $p < 0.05$ ), mean analgesic requirement (39 vs. 15 tablets,  $p < 0.05$ ), time for complete wound healing (84 vs. 49 days,  $p < 0.05$ ). At the mean follow-up of 30 months, 2 patients from the wide excision and open granulation group and one patient from the radiofrequency sinus excision group developed recurrence. **Conclusion:** These findings suggest that sinus excision with radiofrequency is a simple and swift procedure. It needs a short hospital stay and is associated with less postoperative pain and early resumption to work. As compared to excision and healing by granula-

tion technique, the radiofrequency sinus excision procedure achieves faster wound healing and a better outcome.

Copyright © 2006 S. Karger AG, Basel

### Introduction

Pilonidal sinus disease consists of complex symptoms with presentations ranging from asymptomatic pits to painful draining lesions that are predominantly located in the sacro-coccygeal region. Because of high incidences of postoperative complications and late recurrences after operative therapy of this disease [1], the optimal treatment strategy is still a matter of discussion [2].

Radical excision has been the most widely practiced surgical procedure for the treatment of pilonidal disease. The entire sinus is excised along with surrounding tissue down to the post sacral fascia. The defect may be left open to granulate [3, 4], or is closed by primary suturing [5]; or by injection of fibrin glue [6]. Partial closure by marsupialization is another option [7]. Excision with primary closure reduces the healing time, but wound infections and recurrence rates are generally high [8]. To obviate these problems more complex procedures like closure by Z-plasty, asymmetric flap, rhomboid or myocutaneous advancement flaps have been advocated [9]. These have succeeded in reducing the recurrence rate, but they need expertise, require longer operative periods and postoperative hospital stay [10]. Bascom's technique of 'clef-

© S. Karger AG, Basel

**PROOF Copy  
for personal  
use only**

ANY DISTRIBUTION OF THIS  
ARTICLE WITHOUT WRITTEN  
CONSENT FROM S. KARGER  
AG, BASEL IS A VIOLATION  
OF THE COPYRIGHT.

KARGER

Fax +41 61 306 12 34  
E-Mail karger@karger.ch  
www.karger.com

© 2006 S. Karger AG, Basel  
0253-4886/06/0000-0000\$23.50/0

Accessible online at:  
www.karger.com/dsu

Pravin J. Gupta  
Gupta Nursing Home  
D/9, Laxminagar  
Nagpur, 440022 (India)  
Tel. ■■■■, Fax ■■■■, E-Mail drpjj@yahoo.co.in

closure' has emerged as a popular method, which avoids wound in the midline and thus achieves high success rates [11].

Wide excision and healing by open granulation is favored by many surgeons due to simplicity of the procedure and the low rate of recurrence [12, 13]. However, healing by secondary intention takes longer period and needs regular dressing and meticulous wound care with control of hair growth by shaving the natal cleft regularly [14].

Karydakis operation of asymmetrical excision and closure by use of the advancing flap produces a small wound and thus promotes early healing [15]. Lord and Millar [16] described excision of midline epithelial follicles under local anesthesia followed by brushing of the tract to remove hairs within the granulation-lined tract. A 'lay open' method is another minimally invasive technique which can be performed on outpatient basis and has a low recurrence rate [17].

With our previous experience of performing a 'lay open' of the anal fistula [18] and pilonidal sinus [19] using a radiofrequency device instead of conventional diathermy, we carried out pilonidal sinus excision using similar technique with the help of the radiofrequency device.

The aim of this paper is to describe the technique of radiofrequency sinus excision, and to compare it with the outcome of wide excision and healing by granulation procedure.

## Materials and Methods

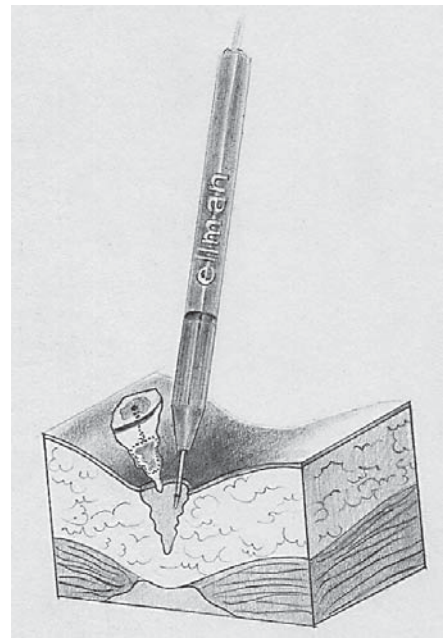
While following Lord and Millar's technique, we modified the procedure by excising the complete tract with a radiofrequency device instead of brushing it, and then leaving the wound open for healing by secondary intention.

### Radiofrequency Surgery

Radiofrequency surgery is a method of achieving simultaneous cutting and coagulation of the tissue using the power of waves at a frequency that is used for radio broadcasting. An Ellman dual frequency radiofrequency generator (Ellman International, Ocean-side, N.Y., USA) was used to carry out the complete procedure.

This study was carried out at Fine Morning Hospital, Nagpur, India, between July 2000 and December 2001, with a follow-up that continued until December 2004. The study was approved by the national ethical committee and was performed according to the Declaration of Helsinki. Informed consent was obtained from all the patients.

44 patients with chronic sacro-coccygeal pilonidal sinus disease were randomized into two groups A and B. Patients from group A were operated by wide excision and open granulation (WEG) technique and those from group B underwent radiofrequency sinus



**Fig. 1.** Radiofrequency sinus excision procedure.

excision (RSE). Randomization was done by sealed envelopes, which were opened by the operation room nurse on patient's arrival in the operation room.

*Inclusion Criteria.* Patients who had actively draining sinuses, or with residual pilonidal disease after drainage of acute abscess or burst abscess were considered for this study. Patients presenting with acute abscess were excluded.

The same surgeon performed both the procedures under general anesthesia using intravenous propofol.

*Wide Excision and Open Granulation Procedure.* Methylene blue was instilled in one of the sinuses. An elliptical incision, which included all the sinuses, was deepened down through the fat to reach the post-sacral fascia. While applying traction, this elliptical part containing skin, fat and the sinus tract was separated from the underlying fascia. The brisk bleeding encountered was secured and the wound edges were trimmed. The wound was covered by an elastic supportive dressing.

*Radiofrequency Sinus Excision Procedure.* The sinus openings were identified and methylene blue mixed with hydrogen peroxide was instilled in one of the sinuses. A director probe was then inserted in the sinus opening and using the fine needle electrode the skin and subcutaneous tissue were incised encircling the sinus opening with a margin of at least 1 centimeter around it. A funnel-shaped dissection continued until the inner end of the sinus tract was reached. No attempt was made to deepen the incision to the post-sacral fascia. If the sinuses were found connected with each other, the fistula tract and the skin between the two sinuses were simultaneously excised. The edges of the wound finally created were reshaped to create a cone shaped wound, i.e. widest externally and narrowest internally. The wound was covered with an adhesive dressing (fig. 1).

The operative time was calculated from the time the incision was given and ended with completion of the procedure, i.e. application of dressing.

**Postoperative Care.** Patients were encouraged to mobilize immediately after surgery. No antibiotics were prescribed. Patients were asked to take a tablet containing 10 mg of serratiopeptidase and 50 mg of diclofenac sodium two times a day till they felt pain. The patients were sounded to opt either to continue hospitalization or be discharged if they felt fully comfortable on every evening at 6 p.m. After discharge, the patients were asked to wash the wound twice a day with soap and warm water and to apply a protective dressing over the wound. Patients were called to the office every week or earlier if needed.

Both the groups were evaluated in terms of demographics, symptoms before procedure, operative time and postoperative complications like wound infection, delayed wound healing, and pain. An independent observer assessed the period of hospitalization, number of wound dressings performed in the office, time for complete wound healing, and recurrence. This follow-up was continued till the wound healed completely. Thereafter, the patients were asked to report after at least 30 months of the procedure.

**Table 1.** Patient demographics and pretreatment symptoms

	Radiofrequency sinus excision (n = 21)	Wide excision and healing by open granulation (n = 23)
Mean age, years (SD)	22.20 (3.4)	23.10 (2.9)
Male:Female	16:5	17:6
Symptoms (n patients)		
Discharge	20	21
Pain	18	17
Itching	11	11
Bleeding	2	1

**Table 2.** Comparative findings of the postoperative events between wide excision and open granulation and radiofrequency sinus excision technique

	Wide excision and healing by open granulation	Radiofrequency sinus excision	p*
Operation time, min	27 (4.1)	10 (3.3)	<0.05
Hospitalization, h	47 (5)	10 (4)	<0.05
Period off work, days	29 (3.7)	8 (1.3)	<0.05
Analgesic tablets consumed	39 (4.3)	15 (5.5)	<0.05
Wound infection	2	0	NS
Wound dressing			
In hospital	39 (6)	13 (3)	<0.05
Wound healing period, days	84 (14)	49 (8)	<0.05
Recurrence	2	1	NS

Values are mean (SD). NS = Not significant.

\* Student's unpaired t test and  $\chi^2$  test.

### Statistical Analysis

The results are presented as means and standard deviation. Data was entered in to a database and analyzed using statistical software (Graph pad quick Calc, San Diego, Calif., USA). The  $\chi^2$  test and the Student's unpaired t test were used for evaluation and  $p < 0.05$  was considered statistically significant.

### Result

There was no significant difference between gender, age or presenting symptoms in both the groups (table 1).

The results in terms of operative time, period of hospitalization, duration of postoperative pain, resumption to work are given in table 2.

Two patients from the WEG group developed suppurative infection of the wounds in the 3rd week of the procedure. The wounds were irrigated and the discharge was cultured to prescribe appropriate antibiotics. While one wound healed uneventfully thereafter, another continued to remain unhealed with frequent discharge and braking of the overlying skin. No such wound related complications were noticed with the radiofrequency sinus excision group.

The follow-up periods were identical in both the groups. Two patients from the WEG group and 1 patient from the radiofrequency sinus excision group failed to attend the office at 30 months postoperative follow-up. One patient from the radiofrequency sinus excision group and 2 patients from the control group developed recurrence during this period.

## Discussion

Various methods have been proposed to tackle pilonidal sinus disease but no one procedure came to be accepted universally. Recurrences vary with the technique, operator and length of follow-up [20]. An ideal surgical procedure should be one that could be performed as a day care or on outpatient basis. It should be simple to perform, should have a low recurrence rate coupled with a rapid and complete wound healing. It should have minimal after care requirements such as frequent visits to the hospital or dressing needing medical supervision [21].

Many studies have concluded that simpler treatment methods for pilonidal disease carry less morbidity and a low recurrence rate [22, 23]. As the procedure of sinus excision by radiofrequency waves aims at removal of the sinuses alone while causing little damage to the surrounding healthy tissues, it can be termed as a simple and minimally invasive technique.

Contrary to Lord and Millar's technique, radiofrequency sinus excision takes a wider skin incision and creates a funnel shaped wound with removal of the overlying skin. With this maneuver, there is hardly any chance of leaving behind any inflammatory tissue or part of the sinus tract behind. This also prevents forming a dead space under the skin in the early postoperative period, particularly when the buttocks come closer [24].

It has been reported by several researchers that pilonidal sinotomy is an ideal approach with high chances of cure [25]. Limited excision of pilonidal sinus is shown to have a shorter convalescence and better patient satisfaction in comparison to more aggressive excisional methods [5]. The procedure of sinus excision is found superior to excision with primary closure with regard to morbidity and recurrence rates [26]. On similar terms, sinus excision by radiofrequency offers positive advantages over the conventional procedure of excision and healing by open granulation.

Apart from radical scalpel dissection, electrocautery or diathermy has been used for sinus excision and has been found to be an easy and convenient method [27]. With the use of diathermy the duration of surgery was found to be significantly less when compared with scalpel dissection [28]. A loop diathermy has been used with success for acute and chronic pilonidal disease [29].

However, we preferred radiofrequency to carry out the entire procedure. Radio frequency surgery may not be confused with electro surgery, diathermy, spark-gap circuitry, or electrocautery. Unlike electrocautery or diathermy, which works on a frequency between 0.5 and

1.5 MHz, radiofrequency uses a very high frequency current of 4 MHz [30]. Unlike the electrocautery, the tip of the electrodes used in radiofrequency remains cold during its application [31]. This allows the surgeon to work in direct proximity of the functional tissues that need to be preserved.

In contrast to true cautery, which causes damage similar to 3rd degree burns, the tissue damage that does occur with radiofrequency is very superficial and is comparable to that which occurs with lasers [32]. The radiofrequency device allows simultaneous cutting and coagulation of tissues in an atraumatic manner in contrast to the traditional electrosurgical devices. With radiofrequency, the targeted tissue temperatures stay localized within a 60–90°C range thus limiting heat dissipation and avoiding damage to adjacent healthy tissue. In juxtaposition, electrocautery, diathermy, or laser temperatures are significantly high (750–900°C) and result in significant heat propagation far in excess of the therapeutic needs [33, 34]. The radiofrequency waves have a property of sealing small blood vessels while dissecting the tissues without creating any char [35, 36]. Use of electrocautery or diathermy invariably results in burning of the adjacent healthy tissues and causes more pain and delay in wound healing [37].

Different malleable electrodes are available with the radiofrequency device that could be selected to suit the requirements of sinus excision like incision, shaping of the wound edges and coagulation of the bleeding points [38].

A 30-month follow-up of the patients seems to be adequate to evaluate the efficacy and outcome of the procedure [39, 40]. While the radiofrequency sinus excision can be performed as a day-care surgery, longer duration of hospital stay and greater consumption of inpatient hospital resources are associated with the wide excision and repair techniques.

It is, however, admitted that this study of 44 patients is too small to permit final conclusions to be drawn concerning significant advantages of one form of treatment over the other. It is, nonetheless, felt that there is a future for this technique either as a primary treatment or as an adjunct to surgery in refractive cases of symptomatic pilonidal sinus disease.

## Acknowledgement

I am indebted to Dr. P.S. Heda for valuable technical assistance and Dr. Ms. S. Kalaskar for statistical correction.

## References

- 1 Flamein R, Slim K, Grandjean JP: Surgery of pilonidal sinus: what is the preferred technique? *Ann Chir* 2005;130:573–576.
- 2 Mentés O, Bağcı M, Bilgin T, Coskun I, Özgül O, Özdemir M: Management of pilonidal sinus disease with oblique excision and primary closure: results of 493 patients. *Dis Colon Rectum* 2006;49:104–108.
- 3 Holmebakk T, Nesbakken A: Surgery for pilonidal disease. *Scand J Surg* 2005;94:43–46.
- 4 Blanco G, Giordano M, Torelli I: Surgical treatment of pilonidal sinus with open surgical technique. *Minerva Chir* 2003;58:181–187.
- 5 Mohamed HA, Kadry I, Adly S: Comparison between three therapeutic modalities for non-complicated pilonidal sinus disease. *Surgeon* 2005;3:73–77.
- 6 Seleem MI, Al-Hashemy AM: Management of pilonidal sinus using fibrin glue: a new concept and preliminary experience. *Colorectal Dis* 2005;7:319–322.
- 7 Spivak H, Brooks VL, Nussbaum M, Friedman I: Treatment of chronic pilonidal disease. *Dis Colon Rectum* 1996;39:1136–1139.
- 8 Iesalnieks I, Furst A, Rentsch M, Kaich KW: Primary midline closure after excision of pilonidal sinus is associated with a high recurrence rate. *Chirurg* 2003;74:461–468.
- 9 Chintapatla S, Safarani N, Kumar S, Haboubi N: Sacrococcygeal pilonidal sinus: historical review, pathological insight and surgical options. *Tech Coloproctol* 2003;7:3–8.
- 10 Lee HC, Ho YH, Seow CF, Eu KW, Nyam D: Pilonidal disease in Singapore: clinical features and management. *Aust NZ J Surg* 2000;70:196–198.
- 11 Zorcolo L, Capra F, Scintu F, Casula G: Surgical treatment of pilonidal disease. Results with the Bascom's technique. *Minerva Chir* 2004;59:387–395.
- 12 Blanco G, Giordano M, Torelli I: Surgical treatment of pilonidal sinus with open surgical technique. *Minerva Chir* 2003;58:181–187.
- 13 Chiedozi LC, Al-Rayyes FA, Salem MM, Al-Haddi FH, Al-Bidewi AA: Management of pilonidal sinus. *Saudi Med J* 2002;23:786–788.
- 14 Testini M, Piccinni G, Miniello S, Di Venere B, Lissidini G, Nicolardi V, Bonomo GM: Treatment of chronic pilonidal sinus with local anaesthesia: a randomized trial of closed compared with open technique. *Colorectal Dis* 2001;3:427–430.
- 15 Anyanwu AC, Hossain S, Williams A, Montgomery AC: Karydakos operation for sacrococcygeal pilonidal sinus disease: experience in a district general hospital. *Ann R Coll Surg Engl* 1998;80:197–199.
- 16 Lord PH, Millar DM: Pilonidal sinus: a simple treatment. *Br J Surg* 1965;52:298–300.
- 17 Al-Homoud SJ, Habib ZS, Abdul Jabbar AS, Isbister WH: Management of sacrococcygeal pilonidal disease. *Saudi Med J* 2001;22:762–764.
- 18 Gupta PJ: Anal fistulotomy with radiofrequency. *Dig Surg* 2004;21:72–73.
- 19 Gupta PJ: Radiofrequency incision and lay open technique of pilonidal sinus (clinical practice paper on modified technique). *Kobe J Med Sci* 2003;49:75–82.
- 20 Hull TL, Wu J: Pilonidal disease. *Surg Clin N Am* 2002;82:1169–1185.
- 21 Destito C, Romagnoli A, Pucello D, Mercuri M, Marin AW: Pilonidal sinus: long term results of excision and closure technic: review of the literature. *G Chir* 1997;18:441–446.
- 22 Zieger K: Complications after surgery for pilonidal cyst: an introduction to a new debate on a 'costly' disease. *Ugeskr Laeger* 1999;161:6056–6058.
- 23 Petersen S, Koch R, Stelzner S, Wendlandt TP, Ludwig K: Primary closure techniques in chronic pilonidal sinus: a survey of the results of different surgical approaches. *Dis Colon Rectum* 2002;45:1458–1467.
- 24 Oncel M, Kurt N, Kement M, Colak E, Eser M, Uzun H: Excision and marsupialization versus sinus excision for the treatment of limited chronic pilonidal disease: a prospective, randomized trial. *Tech Coloproctol* 2002;6:165–169.
- 25 Al-Naami MY: Outpatient pilonidal sinotomy complemented with good wound and surrounding skin care. *Saudi Med J* 2005;26:285–288.
- 26 Gencosmanoglu R, Inceoglu R: Modified lay-open (incision, curettage, partial lateral wall excision and marsupialization) versus total excision with primary closure in the treatment of chronic sacrococcygeal pilonidal sinus: a prospective, randomized clinical trial with a complete two-year follow-up. *Int J Colorectal Dis* 2005;20:415–422.
- 27 Shafik A: Electrocauterization in the treatment of pilonidal sinus. *Int Surg* 1996;81:83–84.
- 28 Duxbury MS, Blake SM, Dashfield A, Lambert AW: A randomised trial of knife versus diathermy in pilonidal disease. *Ann R Coll Surg Engl* 2003;85:405–407.
- 29 Shpitz B, Kaufman Z, Kantarovsky A, Reina A, Dinbar A: Definitive management of acute pilonidal abscess by loop diathermy excision. *Dis Colon Rectum* 1990;33:441–442.
- 30 Gananadha S, Daniel S, Zhao J, Morris DL: An experimental evaluation of ablation devices for the local treatment of the liver resection edge. *Eur J Surg Oncol* 2005;31:528–532.
- 31 Liao WL, Hedman TP, Vangness CT Jr: Thermal profile of radiofrequency energy in the inferior glenohumeral ligament. *Arthroscopy* 2004;20:603–608.
- 32 Seeger J, Zenev E, Gundlach P, Stein T, Muller G: Bipolar radiofrequency-induced thermotherapy of turbinate hypertrophy: pilot study and 20 months' follow-up. *Laryngoscope* 2003;113:130–135.
- 33 Filingeri V, Gravante G, Baldessari E, Casciani CU: Radiofrequency fistulectomy vs. diathermic fistulotomy for submucosal fistulas: a randomized trial. *Eur Rev Med Pharmacol Sci* 2004;8:111–116.
- 34 Podnos YD, Williams RA: Fires in the operating room. *Bull Am Coll Surg* 1997;82:■■■■.
- 35 Hall DJ, Littlefield PD, Birkmire-Peters DP, Holtel MR: Radiofrequency ablation versus electrocautery in tonsillectomy. *Otolaryngol Head Neck Surg* 2004;130:300–305.
- 36 Littlefield PD, Hall DJ, Holtel MR: Radiofrequency excision versus monopolar electrocautery for tonsillectomy. *Otolaryngol Head Neck Surg* 2005;133:51–54.
- 37 Filingeri V, Gravante G, Baldessari E, Craboledda P, Bellati F, Casciani CU: A randomised trial comparing submucosal haemorrhoidectomy with radiofrequency bistoury vs. diathermic haemorrhoidectomy. *Eur Rev Med Pharmacol Sci* 2004;8:79–85.
- 38 Kainz C, Tempfer C, Sliutz G, Breitenecker G, Reinthaller A: Radiosurgery in the management of cervical intraepithelial neoplasia. *J Reprod Med* 1996;41:409–414.
- 39 Breuninger H: Treatment of pilonidal sinus and acne inversa. *Hautarzt* 2004;55:254–258.
- 40 Miocinovic M, Horzic M, Bunoza D: The treatment of pilonidal disease of the sacrococcygeal region by the method of limited excision and open wound healing. *Acta Med Croatica* 2000;54:27–31.