

Radiowave Surgery Case Report

A. HOFMANN, M. WÜSTNER, AND B. CIRIC

ABSTRACT: This case report deals with a 90-year-old female patient who underwent restorative surgery by using radio waves. The extensive involvement with the cylindroma of her hairy scalp, using radio wave surgery, was atraumatically removed. The unequivocal advantage of this operation technique with its quick healing process is unmatched.

Key Words: *Cylindroma, Radiowave, Quick healing*

In plastic surgery atraumatic operation techniques are important for the healing process and the aesthetic result. Yet, the classic operation technique of working with the scalpel is still a standard. For an incision, pressure on the skin with a scalpel is necessary. However, problems arise when exact incisions are necessary on uneven parts of the body with different elasticity, displacement, and deformation (e.g., in the face). As opposed to this, incisions with the electric knife are possible on the tissue almost without pressure. However, a disadvantage is the burning trauma of the edges of the wound, implying the danger of healing disorder and scar formation. The first clinical experiences with radio wave surgery are leading to optimism as a solution for the abovementioned problems.

HISTORY

A 92-year-old patient suffered from cylindroma of the hairy scalp (caput medusae) for nearly 30 years. The still vigorous lady (who lives alone and provides for herself) had asked for assistance from various clinics over the years. Yet, each time she was refused because of inoperability. According to the patient's wish, we eventually removed all cylindromae by using radio wave surgery with local anesthesia. The ambulant operation and the postoperative healing of the wound went well and astoundingly quick. After a few months, the hair grew normal again and the patient was pleased.

*Department of Plastic and Reconstructive Hand and Microsurgery,
Clinic Rosengasse, D-89081 Ulm, Germany.*

*Address correspondence and reprint requests to: Dr. A. Hofmann,
Department of Plastic and Reconstructive Hand and Microsurgery,
Clinic Rosengasse, D-89081 Ulm, Germany.*

DISCUSSION

Numerous treatments with radio surgery have shown that unequivocal advantages can be attained by means of a very atraumatic, quick, and extremely precise operation technique. Yet, radio wave surgery is not to be considered as a fundamental alternative to the scalpel and electrocautery. Radio wave surgery is a method that uses high frequency (4 MHz) radio waves instead of heat to cut and coagulate tissue without the burning effect that is common with traditional electro-surgical devices and cautery equipment. The resistance of tissue to the spread of radio wave energy produces heat within the cell, causing the water within the cell to volatilize and destroy the cell without damaging other cellular layers, thereby creating the incision. In addition, radio waves can be used to seal small blood vessels without creating any char, whereas the cautery or electro-surgical instruments create heat in the tip of the instrument, sealing with transferred heat and therefore damaging adjacent tissues.

The radio wave surgical unit creates an exact incision that can be performed with the least possible collateral tissue destruction because the wire electrode remains cold due to the emittance of fine tungsten. The radio wave surgical instrument has many advantages of the laser without the risk of misdirected reflected beams and prolonged healing periods or expense, although its use may be contraindicated for patients with pacemakers. The patented Ellman Radio-Surgical Device operates at 3.8 Mhz (3,800,000 million cycles per second) and delivers four wave forms such as pure filtered wave forms for microsmooth cutting, fully rectified ones for blended cutting and coagulation, and partially rectified waves forms for hemostasis and for bipolar and fulgurating current.

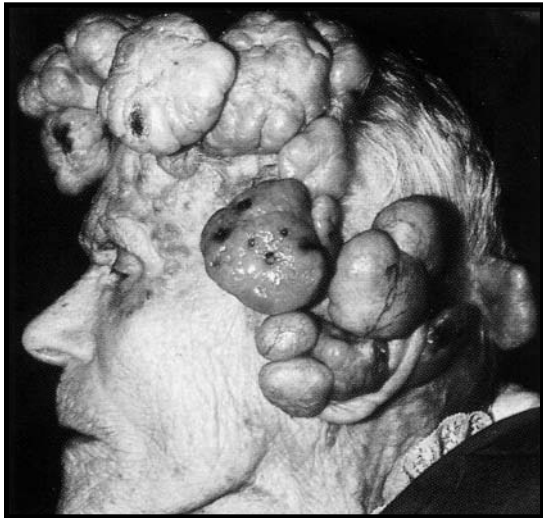


Figure 1.
A 92-year-old female patient
with involvement of
cylindroma caput medusae.

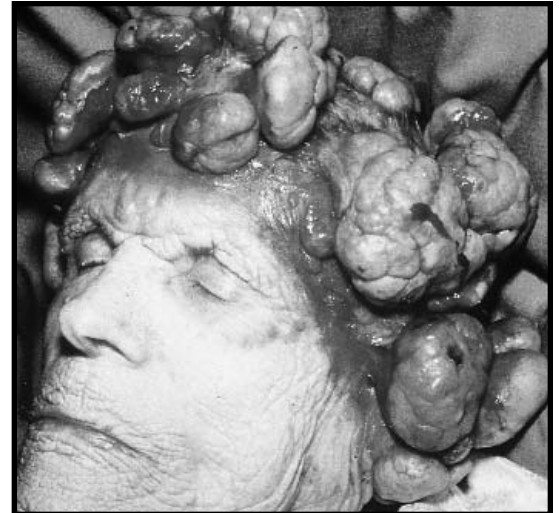

Figure 2.
Incisions being made
with radiowave and
Micro Vari-Tip Electrode

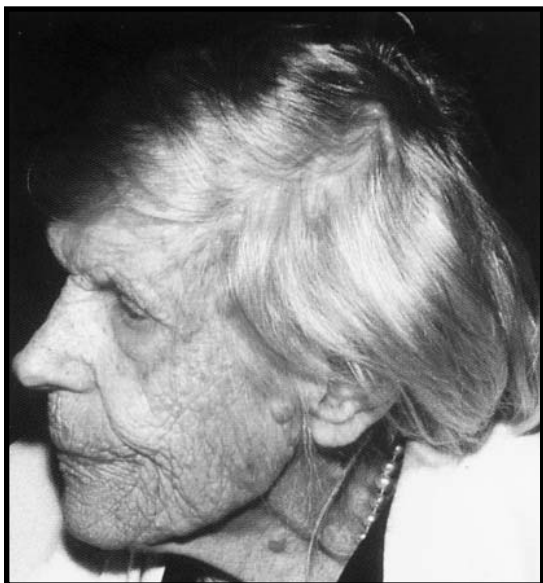
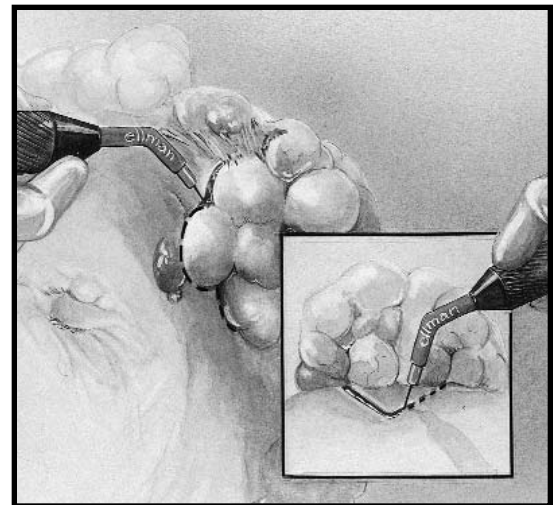
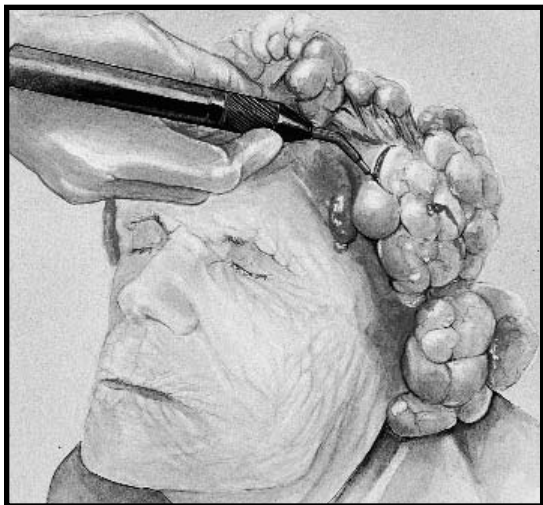



Figure 3.
Six months postoperative.
Note normal hair growth.



REFERENCES

1. Pollock CV: In *Electrosurgery of the Skin*. New York, 1991.
2. Schultz BC, McKinney P: In *Office Practice of Skin Surgery*. Philadelphia, 1985.

3. Turner, Cohen, Voet, Stephen, Weinsten: In *Analysis of Tissue Margins of Cone Biopsy Specimens Obtained with "Cold Knife" CO₂ and Na: YAG Lasers and Radiofrequency Surgical Unit*.
4. Bisaccia, Scarborough: *Blepharoplasty with radiosurgical instrumentation*. *Cosmet Dermatol* 1995; 8.