

ORIGINAL RESEARCH

Bipolar Radiofrequency Dissection Tonsillectomy: A Prospective Randomized Trial

Sameh M. Ragab, MS, MD, FRCSED, Tanta, Egypt

OBJECTIVES: To conduct a prospective randomized controlled study presenting and comparing bipolar radiofrequency dissection tonsillectomy (BRDT) to cold dissection tonsillectomy (CDT) regarding intra-operative blood loss, operative time, postoperative pain, and postoperative complications including hemorrhage.

MATERIALS AND METHODS: From January 2004 to March 2005, 200 children planned to undergo tonsillectomy were included in this study. Children were prospectively randomized into two equal groups: bipolar radiofrequency dissection tonsillectomy and cold dissection tonsillectomy. The operative time and intra-operative blood loss were recorded. Children were asked to record their pain on a standardized visual analog scale on days 1, 4, 7, and 14. All children were reviewed on the 4th, 7th, and 14th day after surgery. Postoperative complications were recorded and dealt with.

RESULTS: There was a shorter operative time (mean 8.5 minutes, $P < 0.001$) in the radiofrequency group. BRDT showed a decrease of 7 minutes in the mean when compared to the CDT group. The amount of blood lost during BRDT was minimal (mean 13 cc), with a mean difference of 69 cc when compared to CDT ($P < 0.001$). There was no statistical significant difference in pain score between the two groups except in the first postoperative day where the BRDT demonstrated a statistically significant lower parameters ($P < 0.05$). No evidence for statistically significant difference between the two groups regarding postoperative complications.

CONCLUSION: BRDT is a new, easy, and safe technique that offers a complete eradication of the tonsillar disease, short operating time, minimal intra-operative blood loss, and a suitable cost with no additional increase in postoperative pain and hemorrhage when compared to the conventional CDT. Our experience promotes BRDT as the preferred method of tonsillectomy.

EBM RATING: A

© 2005 American Academy of Otolaryngology–Head and Neck Surgery Foundation, Inc. All rights reserved.

Tonsillectomy is one of the most frequent surgical procedures performed worldwide. New instruments are constantly implemented in attempts to reduce the morbidity of tonsillectomy. Changes in technology have also influenced the surgical methods, with a continuous search for the most efficient technique that mainly reduces intra-operative blood loss, operative time, postoperative hemorrhages, and postoperative pain. Radiofrequency is a technology that operates on fundamental principles of physics and involves the passage of electrical current through tissue to create the desired tissue effect. The probe does not heat, as in electrocautery; rather, the tissue heats in response to the radiofrequency current passing through it. The electrosurgical circuit includes the radiofrequency generator, active electrode, grounding pad, and the patient. It produces five distinct waveforms: fully filtered, fully rectified, partially rectified, fulguration, and bipolar. Each of these modes uses a combination of frequency, power, waveform, electrode size, and time of application to produce a tissue temperature that will result in a predictable histological effect.^{1,2} Radiofrequency has been used in gynecologic, plastic surgical, and dermatologic practice for more than 30 years and is a well-established and valuable tool in these fields of medicine. In otolaryngology, it has been used in palatal, turbinate, and tonsillar reduction, taking advantage of its ablative properties. We introduced its use in performing adenoidectomy³ and creating myringotomies⁴ in human beings. To my knowledge there are no reports in the literature discussing the use of bipolar radiofrequency waves in performing complete tonsillar excision, with previous studies mainly describing it as a tool for tonsillar reduction using the property of radiofrequency tissue ablation.

Therefore, this study was conducted in a prospective randomized controlled manner to present and compare bi-

From the Department of Otolaryngology–Head & Neck Surgery, Tanta Faculty of Medicine and University Hospitals.

Reprint requests: Sameh M. Ragab, Taiba Hospital, P.O.Box. 66482, Bayan 43755, Kuwait.

E-mail address: sragab@doctors.org.uk.

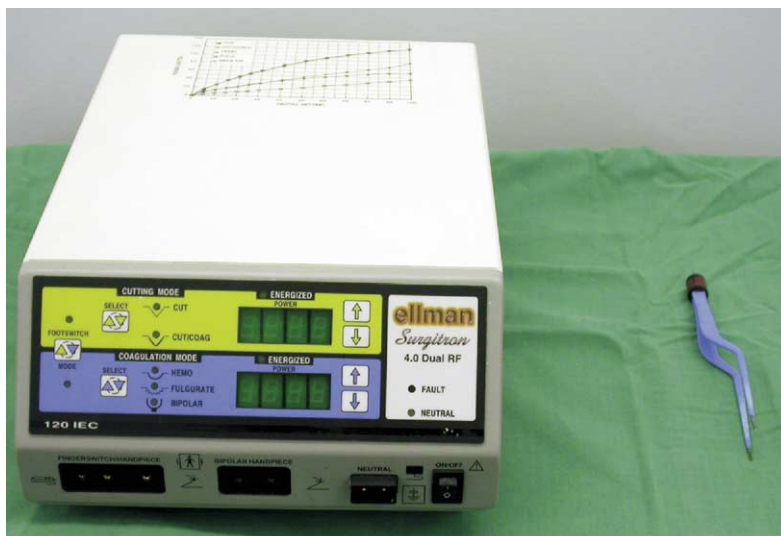

Figure 1 The radiofrequency apparatus and the bipolar forceps.

polar radiofrequency dissection tonsillectomy (BRDT) to cold dissection tonsillectomy (CDT) regarding intra-operative blood loss, operative time, postoperative pain, and postoperative complications including hemorrhage.

MATERIALS AND METHODS

The study was conducted between January 2004 and March 2005, including 200 patients (84 male, 116 female) whose age was 9 to 16 years (mean of 12 ± 2 years) and planned to undergo tonsillectomy in the Department of Otolaryngology–Head and Neck Surgery, Taiba Hospitals, Kuwait. Two hundred children were prospectively randomized into 2 equal groups: bipolar radiofrequency dissection tonsillectomy and cold dissection tonsillectomy. The study protocol and consent forms were approved by the research review committee. Children were subjected to detailed history taking, thorough examination and skull lateral view X-ray. Exclusion criteria included history of quinsy, bleeding disorders, chronic debilitating diseases, craniofacial anomalies, and the need to perform any other procedure with tonsillectomy.

Operative Technique

All cases were done under general anesthesia via a cuffed transoral endotracheal tube. The child was rendered supine with the head of the operating table 10 to 20 degrees below the horizontal plane and a sand bag under his shoulders. The mouth was held open with a Boyle-Davis mouth gag. In BRDT, a radiofrequency bipolar forceps, connected to a radiofrequency apparatus model Ellman Surgitron 4 MHz (Ellman International, New York, USA) was used to perform a complete dissection tonsillectomy. The power was adjusted to a power grade of 40 in a bipolar mode. The Boyle-Davis mouth gag was removed at the end of the operation and the patient was turned back to the anesthetist for recovery from general anesthesia. [Figure 1](#) shows the

radiofrequency apparatus and the bipolar forceps. Cold dissection tonsillectomy used blunt dissector dissection and snares, with bipolar diathermy and rescue ligature for hemostasis.

The intra-operative blood loss was calculated. The operative time was kept by an independent nurse and estimated from insertion to removal of the Boyle-Davis mouth gag. Children were asked to record their pain on a standardized visual analog scale on days 1, 4, 7, and 14. All children were prescribed a standard regimen of paracetamol every 6 hours. All children were reviewed on the 4th, 7th, and 14th day after surgery. Postoperative complications were recorded and dealt with. Parents were asked to report if they had any concern about emetic events, high fever, the need of extra analgesia, and the time needed to return to preoperative diet and activities.

Statistical Methods

In order to maintain exactly equal treatment numbers in both groups, randomization was done using random blocks. At the time of randomization, both the patient and the investigator were not aware of the group assignment. The analysis was done using SPSS for Windows statistics software package. Data were expressed as mean \pm standard deviation (SD). *P* values < 0.05 were considered significant. Parametric tests such as *t* test were applied for data that followed a normal distribution. Nonparametric tests such as Mann-Whitney *U* test and χ^2 test were applied for data that did not follow a normal distribution.

RESULTS

Flow Chart of the Study

Sixteen patients were lost in the follow-up settings; 9 in the radiofrequency and 7 in the conventional groups.

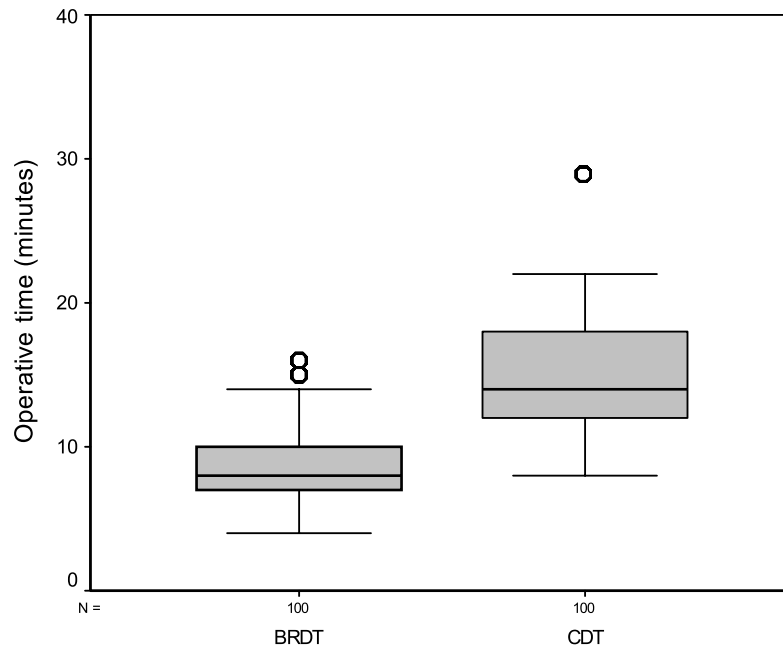


Figure 2 Boxplots of operative time.

Operative Time

There was a shorter operative time (mean 8.5, median 8, range 4-16 minutes) in the radiofrequency group ($P < 0.001$). BRDT showed a decrease of 7 minutes in the mean and 6 minutes in the median when compared to the CDT group. Figure 2 shows boxplots of the operative time.

Blood Loss

The amount of blood lost during BRDT was minimal (mean 13, median 7, range 0-70 cc), with a mean difference of 69 cc

and a median difference of 59 cc, when compared to CDT ($P < 0.001$). Figure 3 shows boxplots of the intra-operative blood loss.

Pain Score

There was no statistically significant difference in pain score between the two groups except in the first postoperative day where the BRDT demonstrated statistically significant lower parameters (mean 8.5, median 8, range 6-10) when compared to CDT (mean 9, median 9, range 7-10) ($P < 0.05$).

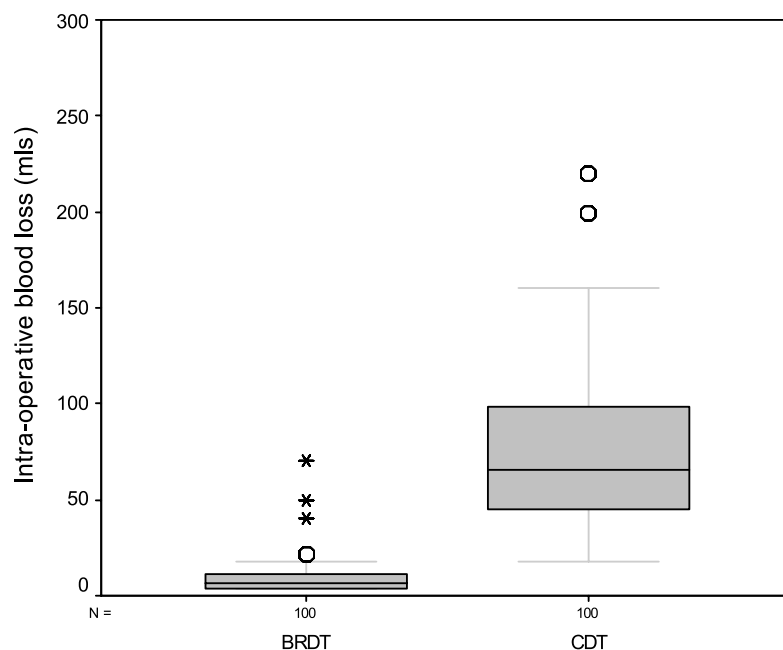


Figure 3 Boxplots of intra-operative blood loss.

Postoperative Sequelae and Complications

There was no evidence of statistically significant difference between the two groups regarding postoperative emesis, fever, administration of analgesia, and the time needed to return to preoperative diet and activities. One case of reactionary hemorrhage and two cases of secondary hemorrhage were reported in the CDT, whereas BRDT experienced a single case of secondary hemorrhage. All cases responded to conservative management except the case of reactionary hemorrhage in CDT, which was taken back to the theatre to control bleeding.

DISCUSSION

Various techniques of tonsillectomy have been described in the literature, among which cold dissection tonsillectomy is considered by many to represent the gold standard. The ultimate goal in any surgery is to reach the ideal surgical procedure. An ideal tonsillectomy should attain easiness of the procedure, short operating time, minimal blood loss, complete eradication of the disease, suitable cost, and no complications. To ensure that optimal methods are being used in tonsillectomy, surgeons should not only assess the current surgical techniques, but also implement any technology in this field. The radiofrequency energy is an alternative technology that has many advantages: 1) hemostatic, 2) bacteria-free method, 3) better and faster healing than electrocautery, 4) cut without exerting any pressure, and 5) a low cost.^{1,2} In the field of tonsillar surgery, radiofrequency was mainly described as a tool for tonsillar reduction using the property of radiofrequency tissue ablation. However, some concerns have been raised. First, the ablative procedure does not eliminate the crypts of the tonsils, possibly limiting its efficacy for chronic or recurrent infections. Second, there is a possibility that the remaining tonsillar tissue will grow with recurrence of symptoms. Third, there exists the inability to send tissues for histopathological examination, especially if a suspicion of neoplasm has been raised. In this study, the surgical method of bipolar radiofrequency dissection tonsillectomy in children was presented and compared with cold dissection tonsillectomy. BRDT showed a significant decrease in operative time and intra-operative blood loss, whereas no difference was found in the complication rate including postoperative hemorrhage. BRDT allowed (84%) less mean blood loss than CDT since both dissection and hemostasis were simultaneous. It also showed (45%) shorter mean operative time than the conventional method. Minimal blood loss and short operating time help to prevent postoperative complications such as hypovolemia and postoperative airway problems including pulmonary edema, especially in susceptible young children.⁵ The overall incidence of reactionary and secondary hemorrhages in this study was 0.5% (0% BRDT and 1% CDT) and 1.5% (1% BRDT and 2% CDT) respectively. These figures compare favorably with most of the cold tonsillectomy series.^{6,7} On the other hand, it has been found that even though electrocautery reduces operative time

and intra-operative blood loss, it significantly increases postoperative hemorrhages with figures up to 7% reactionary hemorrhage and 12.5% secondary hemorrhage.⁶⁻¹¹ On the other hand, O'Leary and Vorrath¹² published a recent prospective, nonrandomized cohort study of postoperative hemorrhage after cold dissection and diathermy tonsillectomy in more than 4500 cases. The relative risk of bleeding after diathermy tonsillectomy was 1.30, when compared to cold tonsillectomy, with more secondary hemorrhages and bleeds in excess of 500 cc in the latter group. However, the difference in postoperative bleeding between both techniques was not statistically significant.

Postoperative pain was recorded in the 1st, 4th, 7th, and 14th day during the first 2 weeks after surgery. No statistically significant difference between BRDT and CDT has been found except in the day of the operation where BRDT showed a lower pain scores. It has been known that early postoperative pain may be more intense after mechanical trauma of cold tonsillectomy, whereas hot methods may have a higher incidence of late postoperative pain. Akural et al¹³ studied the use of ultrasonic-activated scalpel and blunt dissection in the same patients. One of the tonsils was used as the control (blunt dissection), whereas the other side was removed with the ultrasonic-activated scalpel. They observed that the side operated on with the ultrasonic-activated scalpel was associated with decreased severity in pharyngeal pain on the day of the operation but increased pharyngeal pain and otalgia during the second postoperative week compared with the side using blunt dissection. Electrodissection tonsillectomy has been reported to increase postoperative pain in pediatric patients after hospital discharge.^{10,11} In this study, BRDT did not face the general problem of electrocautery in which postoperative pain is often markedly increased compared with the cold dissection tonsillectomy. The use of radiofrequency waves in the bipolar mode provides a pin-point coagulation with minimal lateral heat, thus reducing the depth of lateral thermal injury and, hence, decreasing scarring and pain.

CONCLUSION

BRDT is a new, easy, and safe technique that offers a complete eradication of the tonsillar disease, short operating time, minimal intra-operative blood loss, and a suitable cost with no additional increase in postoperative pain and hemorrhage when compared to the conventional CDT. Our experience promotes BRDT as our preferred method of tonsillectomy.

REFERENCES

1. Maddern BR. Electrosurgery for tonsillectomy. *Laryngoscope* 2002; 112(8 Pt 2):11–3.
2. Smith TL, Smith JM. Electrosurgery in otolaryngology–head and neck surgery: principles, advances, and complications. *Laryngoscope* 2001; 111(5):769–80.

3. Shehata EM, Ragab SM, Behiry AB, et al. Telescopic-assisted radiofrequency adenoidectomy: a prospective randomized controlled trial. *Laryngoscope* 2005;115(1):162–6.
4. Ragab SM. The effect of radiofrequency and mitomycin C on the closure rate of human tympanostomy. *Otol Neurotol* 2005;26(3):355–60.
5. Wiatrak BJ, Myer III, CM Andrews TM. Complications of adenotonsillectomy in children under 3 years of age. *Am J Otolaryngol* 1991; 12(3):170–2.
6. Lee MS, Montague ML, Hussain SS. Post-tonsillectomy hemorrhage: cold versus hot dissection. *Otolaryngol Head Neck Surg* 2004;131(6): 833–6.
7. Tami TA, Parker GS, Taylor RE. Post-tonsillectomy bleeding: an evaluation of risk factors. *Laryngoscope* 1987;97(11):1307–11.
8. Siodlak MZ, Gleeson MJ, Wengraf CL. Post-tonsillectomy secondary haemorrhage. *Ann R Coll Surg Engl* 1985;67(3):167–8.
9. Saleh HA, Cain AJ, Mountain RE. Bipolar scissor tonsillectomy. *Clin Otolaryngol* 1999;24(1):9–12.
10. Nunez DA, Provan J, Crawford M. Postoperative tonsillectomy pain in pediatric patients: electrocautery (hot) vs cold dissection and snare tonsillectomy—a randomized trial. *Arch Otolaryngol Head Neck Surg* 2000;126(7):837–41.
11. Blomgren K, Qvarnberg YH, Valtonen HJ. A prospective study on pros and cons of electrodissection tonsillectomy. *Laryngoscope* 2001; 111(3):478–82.
12. O’Leary S, Vorrath J. Postoperative bleeding after diathermy and dissection tonsillectomy. *Laryngoscope* 2005;115(4):591–4.
13. Akural EI, Koivunen PT, Teppo H, et al. Post-tonsillectomy pain: a prospective, randomised and double-blinded study to compare an ultrasonically activated scalpel technique with the blunt dissection technique. *Anaesthesia* 2001;56(11):1045–50.